

MASSACHUSETTS INSTITUTE OF TECHNOLOGY
ARTIFICIAL INTELLIGENCE LABORATORY

A.I. Memo No. 363

June 1976

OCCLUSION CLUES AND SUBJECTIVE CONTOURS

by

Kent A. Stevens

ABSTRACT. The paper describes some experiments with a visual agnosia patient who has lost the ability to perceive subjective contours. The patient's interpretations of simple examples of occlusion indicate that he fails to notice monocular occlusion clues, as well. The findings support the hypothesis that subjective contours are constructions that account for occluded figures, in the absence of objective edges. The patient's ability to perceive contours by stereopsis demonstrates that stereopsis independently gives rise to *disparity contours*. Furthermore, the overall results strongly suggest that the detection of occlusion is modularized, and that the module for detecting monocular occlusion clues is not the same as that which provides occlusion clues on the basis of stereopsis.

This report describes research done at the Artificial Intelligence Laboratory of the Massachusetts Institute of Technology.

INTRODUCTION

Subjective contours are clearly *constructions*: An edge is perceived where no contrast is present. It is unlikely that these contours are merely artifacts that arise from the partial activation of edge or line masks [Kanizsa, 1976; Marr, 1975]. It has been suggested that subjective contours arise during the interpretation of depth cues: "*...a subjective contour is simply the edge of a subjective plane, and a subjective plane is a surface which ought to be present on the basis of available depth cues, but is not except in the mind of the perceiver*" [Coren, 1972].

Marr has suggested that subjective contours are constructed from groupings of *place tokens*. In figure 1, for example, the place tokens are the endpoints of the radial lines. Points, blobs, and even small forms can act as place tokens in contributing towards groupings.

Similar groupings can be seen in dot patterns. In figure 2 groupings of dots give rise to concentric and radial patterns. Like subjective contours, these patterns do not persist under scrutiny.

The similar impressions given by subjective contours and groupings of dots suggests that they are generated by a common grouping mechanism. However, unlike simple groupings, whether or not one perceives a subjective contour is apparently related to *figure-ground* decisions. It is therefore useful to distinguish between the method by which they are *constructed*, and the criteria that leads to their *perception*. A visual agnosia patient has provided some evidence of the latter.

Figure 1 [after Marr, 1975]. The grouping of place tokens into a curvilinear aggregation is probably necessary to define the shape of a subjective contour, but more than grouping is involved in its perception. In this figure, the endpoints of the lines not only serve as place tokens for grouping, but as weak evidence of *occlusion*, as well. A compelling *figure-ground* interpretation therefore takes the central region as a *figure*, wherein it is seen to be brighter and nearer than the radial lines which it partially obscures. If however, one ignores the occlusion clues and interprets these line segments as individual figures (in which case the central region is ground) then the subjective contour is not perceived. The patient was capable only of the latter, two-dimensional interpretation as evidenced by his descriptions over several trials.

Figure 2 [after Glass & Perez, 1973]. Given two copies of a random dot pattern, if one is rotated and superimposed on the other, then a concentric pattern results. A radial pattern arises if one scales rather than rotates one of the patterns. Groupings imposed on random dot interference patterns give rise to perceptual effects that are similar to subjective contours: the illusion does not persist under scrutiny, and yet presents itself strongly in non-foveal vision.




Figure 1



Figure 2

EXPERIMENTS

A patient has evidence of occlusion to the left posterior cerebral artery which caused infarction to the left medial occipital region, and suggestions of other disease to the posterior hemispheres bilaterally. As a result, he has partial right heteronymous hemianopsia, visual agnosia, and amnesia. Relevant to this discussion is that *he does not see subjective contours*.

In spite of his agnosia, his ability to describe drawings is good, especially since he has artistic skill and discusses drawings in terms of "shading", "form" and so forth. Furthermore, he is alert, intelligent, and cooperative. Throughout these experiments, he was unaware that his perception of subjective contours and occlusion was being investigated. Rather, he believed that his visual acuity was being tested.

Two series of presentations were made. The first consisted of subjective contours [see Kanizsa, 1976, pp 48-51; and Marr, 1975, p. 30] and random dot interference patterns [see Glass & Perez, 1973, p. 361]. The second series consisted of computer generated stereograms (see figures 7-10). Included as well were random dot stereograms [Julesz, 1971] of a disk and a square. All stereograms were presented to the patient as transparencies, using a Realist stereo viewer.

The patient's amnesia allowed repeated testing with differing verbal approaches, for rarely did he remember having seen a given figure, even if it had been presented only minutes before.

RESULTS

Subjective contours

The initial series of presentations revealed that the patient perceived no edge where one normally sees a subjective contour. Various approaches were taken to verify this, and I am confident that no edge, line, or boundary could be visualized by the patient, even when it was suggested that a "thin wash of grey" had been applied to one side of the contour, and that he "should be able to see the contrast".

In figure 3, for example, the terminations of the horizontal lines usually give rise to subjective contours. Those terminations that follow the sinusoid are especially effective in suggesting an edge, with illusive impressions of contrast across the edge. The patient described the figure in constructive two-dimensional terms, indicating how the lines on the left were apparently shifted laterally with respect to those on the right. While he noticed that the boundary between them was curved, it was clear that he did not see any edge or contrast effects: he described the curved boundary as being defined only by the way the lines terminated, and that between the endpoints (along the curve) the brightness was the same as elsewhere in the figure. No "illusive contrast" was seen.

Not surprisingly therefore, forms composed of subjective contours were never seen by him. Examples of these are the Kanizsa triangle (see one side of the stereo pair in figure 9), rectangle (figure 8), the disk in figure 1, and the pear-shaped form in figure 5. The location of a *subjective form* could be understood only after its vertices were laboriously pointed out and its periphery traced. Even then, it evidently could not be visualized, for it

would not appear nearer or brighter, nor would it be seen as occluding the background forms.

Occlusion

As mentioned, the presentation of the Kanizsa triangle and rectangle showed that coupled with not seeing the subjective forms, the patient failed as well to interpret the surrounding patterns as partially occluded figures. For example, the Kanizsa triangle illustration was interpreted as three irregular black forms and various line segments. When asked to further describe the black forms, his description was in terms of what was *literally* presented, and not in terms of partially obscured disks. The line segments were described as three disjoint angles or corners (indicated by gesticulation). He rejected the suggestion that they might be the vertices of a triangle, for the sides were obviously incomplete! This fragmented global interpretation persisted during subsequent retrials with the illustration presented at varying distances from the patient. Similarly, the Kanizsa rectangle illustration was consistently described as four stripes and four lines. His failure to include occlusion in his interpretations was explored further.

The patient's first impressions of figure 1 were as follows:

"Please describe what you see."

"... a blank circle with lines going out of it at equal lengths so the end of each line makes another larger circle."

"Where's the smaller circle?"

"... it's not a circle, it's just that nothing has been drawn there."

This is an accurate description of figure 1, of course. However one usually arrives at a simpler interpretation as well: that of a white disk occluding the center of a radial pattern of lines. At least, if this interpretation does not occur immediately, it can be perceived once suggested. Yet the patient could not perceive the occlusion interpretation, even when it was described in detail. It could be understood only after I demonstrated it repeatedly with a small disk of paper on a hand-drawn radial pattern. This interpretation seemed to come to him as a revelation.

Over several trials, figure 4 was interpreted consistently as two rectangles and a square, and not as a square partially occluding a rectangle, even when the latter interpretation was verbally suggested. The occlusion interpretation was demonstrated, as before, with two pieces of paper. After some effort, he understood how that interpretation could apply to the line drawing. Yet later, when asked to draw the figure, although he took care to duplicate the aspect ratios of the three rectangles, the lines that correspond to occluded edges were not made collinear.

Further evidence of his inability to perceive occlusion came in figure 5 wherein he never interpreted the black forms as partially obscured disks. Yet he was immediately impressed by the pear-shaped central region. He did not consider it to be a *figure*, however, for it was not complete: its boundary was suggested only in places (where the disks were occluded). Each such edge was noted as either being convex or concave (not his words, rather he noted this by gesticulation) *relative to the black forms*, and not to the pear-shaped region. Therefore, it was evident that each edge was not seen as an occlusion edge, but merely as part of the boundary of a black form. Globally, he interpreted figure 5 as an arrangement of curiously shaped forms. No variation in this interpretation came from

Figure 3 [after Marr, 1975]. The terminated lines give rise to two vertical subjective contours, and a sinusoidal subjective contour. The latter is especially effective in suggesting an edge, if the figure is interpreted as one grid above another. The patient described the figure only in terms of a two-dimensional arrangement of grids, and could see no subjective contours.

Figure 4. This can be interpreted as a square partially occluding a rectangle, or as two rectangles abutting a square if one does not take the alignment and T-junctions as evidence for occlusion. The patient was capable only of the latter, two-dimensional interpretation.

Figure 5 [from Kanizsa, 1976]. Various occlusion clues give rise to the compelling interpretation of a pear-shaped form in front of a collection of black disks. The patient never came to this interpretation, nor did he see the subjective contours.

Figure 6 [after Kanizsa, 1976]. Rather than see a transparent rectangle above black disks, the patient described the figure in terms of grey and black forms, noting how each pair of forms together made a circular form. The grey-black boundaries were seen to partially define the perimeter of a rectangle, as well.



Figure 3

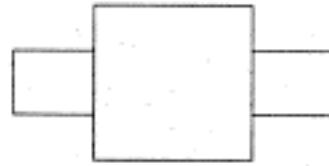


Figure 4



Figure 5




Figure 6

varying his distance from the figure.

In figure 6, usually interpreted as a translucent rectangle lying over various-sized black disks, the partially obscured (grey) portion of each disk was seen as a separate figure from the black portion. Yet he noticed that the grey and black portions together defined circular forms. More globally, he noted that the grey-black boundaries partially defined the perimeter of a rectangle. Amazingly, in spite of his precise observations, he did not see the translucent rectangle.

Random dot interference patterns

After the subjective contours, the dot patterns were presented. The patient had no difficulty in seeing the radial, spiral, and circular patterns. The "centers" of the radial and circular patterns were noticed immediately, followed by descriptions of the flow patterns. Gesticulation indicated his perception when the terminology (e.g., "spiral") was not recalled. In those cases where one usually sees a pattern, the patient did as well, and in those where there was no global pattern, various local groupings were noticed.

The second series of experiments

It was discovered that in the interim between the first and second series of these experiments, the patient had been shown a large number of examples of simple figures occluding other simple figures. He could now respond, for example: "that is a rectangle above a triangle". However, there was strong evidence that this was only an intellectual achievement on the order of his noticing appendages on either side of a simple figure, and

determining the geometry of the occluded figure by counting the visible vertices: He failed to notice the *lack* of smooth continuation when the two portions of the occluded figure were actually shifted relative to each other. Also, if the occlusion was considerable, or if the occluded figure was not simple, then his description was inaccurate.

Stereopsis

The patient's stereopsis was tested with two random dot stereograms. Both were successfully fused, with the disk and square seen as suspended in front of the background. These stereograms were composed of black squares (random dot density was 50 percent), and the 100 by 100 matrix subtended the full field of the stereo viewer. Given this coarse dot pattern, if one were to foveate on the borders of the square and disk, they would appear ragged and discontinuous in places, but would usually appear smooth and continuous in non-foveal vision. However, the patient only saw them as ragged and discontinuous.

The patient's stereopsis having been established, the stereogram versions of the subjective disk, square, and triangle (figures 7, 8 and 9) were presented. They appeared to the patient as if they were "cut out of white paper and suspended". *The edges of these figures were seen as sharp and distinct.* Figure 10, after some difficulty, was interpreted as a rectangle suspended in front of disks. Figures 11 and 12 are his renditions of the stereograms of figures 9 and 10.

The underlying forms in figures 8 and 9 were seen as occluded. For example, in figure 8, the background was described as a black cross, with horizontal and vertical lines.

Figure 7. This is a stereogram version of figure 1. The *disparity contour* which defines the perimeter of the disk was perceived by the patient while the subjective contour in figure 1 was not. In stereo, the disk appeared as if it were "cut out of paper and suspended". No disk was seen in figure 1.

Figure 8 [after Kanizsa, 1976]. This is a stereogram version of the Kanizsa rectangle. In sharp contrast to the patient's inability to perceive the conventional version, the patient perceived the stereo subjective rectangle as having sharp edges, and as *occluding* the underlying forms.

Figure 9 [after Kanizsa, 1976]. The patient saw the stereo Kanizsa triangle as suspended in front of three disks and a line-drawn triangle. His interpretation of the conventional version had been totally fragmented, with no disks or triangles seen.

Figure 10 [after Kanizsa, 1976]. While in this stereogram version of the transparent rectangle illustration the patient had difficulty in seeing the rectangle as being in front of the disks, he did perceive the edges of the disk as distinct.

Figure 11. This is the patient's rendition of the figure 9 stereogram. The triangles were drawn first, followed by the three disks. The background triangle was then emphasized, with the saw-tooth artifact of the computer-generated stereogram included.

Figure 12. The patient's rendition of the figure 10 stereogram. The rectangle was drawn first, with the disks placed later.

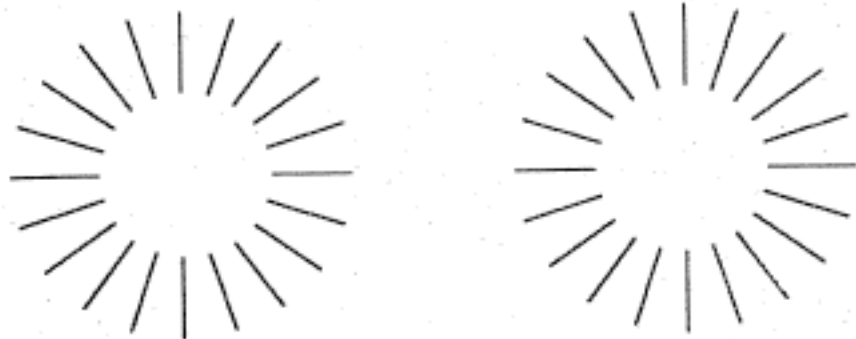


Figure 7

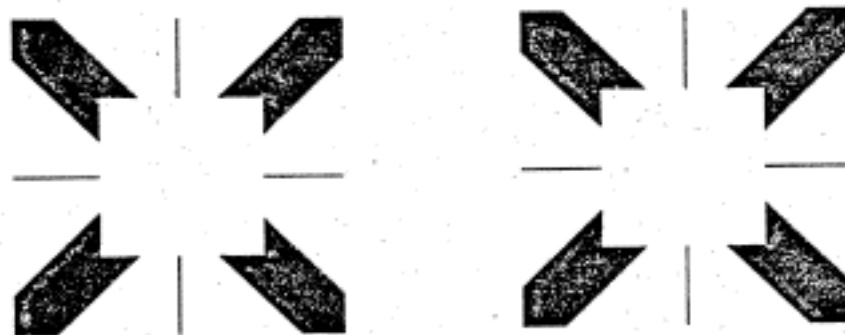


Figure 8

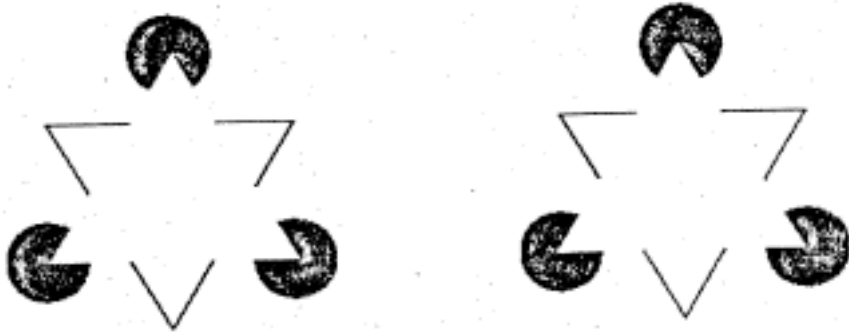


Figure 9



Figure 10

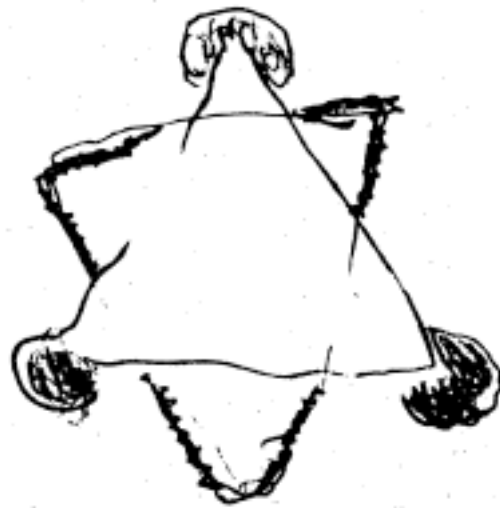


Figure 11

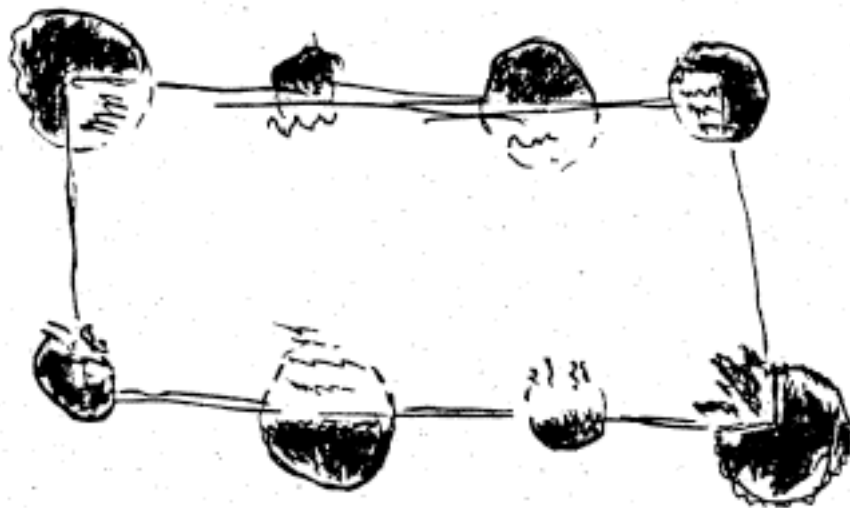


Figure 12

CONCLUSIONS

Subjective contours arise, in part, from occlusion clues

The results support the hypothesis that subjective contours are constructions that account for occluded figures, in the absence of objective edges. Visual evidence that a figure is partially obscured gives rise to the need to "explain" the obscuration. The patient's inability to perceive subjective contours can be explained by his inability to notice *monocular occlusion clues*: If he were not to see these clues, he would have no need to construct the subjective contours.

The patient *was* able to perceive groupings in dot patterns, the sinusoidal terminations of lines in figure 4, and the alignment of edges in figures 6 and 7. The overall shape of regions could be described, even when the region was not bounded by an objective contour. These curvilinear groupings of various place tokens may be the *precursors of subjective contours*. That is, when occlusion cannot be "explained" by an actual edge of some occluding figure, then these groupings are the next best evidence for an edge, hence are visualized as subjective contours.

Stereopsis independently gives rise to contours

Evidently depth ordering by stereopsis independently provides occlusion clues, and these clues allowed the patient to interpret the stereograms as figures partially occluding other figures. The distinctness with which the patient saw the contours in the stereograms indicates that these *disparity contours* are not subjective contours: they are

constructed on the basis of different clues.

The patient saw the boundaries of the random dot stereogram figures as ragged. This suggests that our tendency to see Julesz figures as having smooth boundaries (except under scrutiny) is probably attributable to subjective contours.

The detection of (monocular) occlusion is modularized

The results of the first series of presentations indicated that a number of monocular occlusion clues were not used by the patient. These include: line terminations (with or without smooth continuation); T-junctions; concavities in, or mutilations to, otherwise convex (and simple) figures; and unclosed figures. These various clues contribute toward a common function: the detection of occlusion. The patient's failure to use *any* of them suggests the possibility that a single module utilizes these clues to provide occlusion information, which in turn contributes towards a global figure-ground interpretation. Furthermore, this module is probably not the same as that which provides occlusion clues on the basis of stereopsis.

Acknowledgements: I thank Tedd Judd for introducing me to D.R., the visual agnosia patient then at Boston Veteran's Administration Hospital. Also, Keith Nishihara, Shimon Ullman, and Dr. Tomaso Poggio for many discussions, and especially, Dr. David Marr for his suggestions and insight. This work was conducted at the Artificial Intelligence Laboratory of the Massachusetts Institute of Technology.

References

- Coren, S. 1972. Subjective contours and apparent depth. *Psychological Review*, 79, 359-367.
- Glass, L. & Perez, R. 1973. Perception of random dot interference patterns. *Nature*, 246, 360-362.
- Julesz, B. 1971. *Foundations of Cyclopean Perception*, Chicago: The University of Chicago Press.
- Kanizsa, G. 1976. Subjective contours, *Scientific American*, 234, 48-52 (April issue).
- Lawson, R.B. & Gulick, W.L. 1967. Stereopsis and anomalous contour. *Vision Research*, 7, 271-297.
- Marr, D. 1975. Early processing of visual information, *M.I.T. A.I. Lab. Memo 340*.